

## Original Article : Open Access

## Preclinical appraisal of acute oral toxicity of combination of root extracts of *Saussurea lappa* (Decne.) Sch.Bip. and *Valeriana wallichii* (DC.)

Mrunali S. Potbhare\*,\*\*♦ Rakesh Barik\*\*\* and Deepak S. Khobragade\*\*

\*Institute of Pharmacy, GITAM University, Viazag-530045, Andhra Pradesh, India

\*\*Datta Meghe College of Pharmacy, Salod (H), Datta Meghe Institute of Higher Education and Research (DU), Sawangi-442001, Wardha, Maharashtra, India

\*\*\*School of Pharmacy, GITAM University, Hyderabad-502329, Telangana, India

### Article Info

#### Article history

Received 13 October 2022  
 Revised 29 November 2022  
 Accepted 30 November 2022  
 Published Online 30 December-2022

#### Keywords

*Saussurea lappa* (Decne.) Sch. Bip.  
*Valeriana wallichii* (DC.)  
 Extract  
 OECD  
 Oral acute toxicity

### Abstract

Sometimes, drugs that are not toxic individually can be toxic in combination with other drugs. This is even true for herbal drugs. *Saussurea lappa* (Decne.) Sch.Bip. and *Valeriana wallichii* (DC.) are found to be therapeutically effective for many indications and are safe. But, when they are required to be used in combination for the preparation of a polyherbal formulation, their toxicity in combination needs to be evaluated. The present study evaluates the single-dose (2000 mg/kg) oral acute toxicity of a 1:1 ratio of hydroalcoholic extracts of *S. lappa* and *V. wallichii* according to OECD guideline 423. Various parameters of toxicity in rats were checked for the first 30 min, 4 h, 24 h, 48 h, 7th day, and 14th day after the administration. There were no signs of mortality or morbidity based on the physical examination. The animals were sacrificed on the 14th day, and hemotic, biochemical, and other related parameters were evaluated. All the evaluated parameters showed no significant changes and were within normal limits after administration of a single dose of 2000 mg/kg of drug, indicating the absence of any signs of toxicity at the administered dose. Thus, from the results, it can be concluded that polyherbal extracts consisting of a 1:1 ratio of *S. lappa* and *V. wallichii* have no acute oral toxicity.

### 1. Introduction

It is considered that herbal medicines are very safe. However, this is not true because some plants are extremely toxic and poisonous. The difference between a drug and a poison is its dose. Any drug at a higher dose can be poison, and any poison at an optimum dose can be a drug. Therefore, it is very important to evaluate all the drugs, whether herbal or synthetic, for their toxicity. The toxicity study not only predicts possible toxic effects but also helps in deciding a safe dose. *S. lappa* (family Asteraceae) is a perennial plant found throughout Kashmir and the Himalayas. The *S. lappa* root is traditionally used to treat severe illnesses like headaches, paralysis, deafness, fever, asthma, and ophthalmic conditions (Chhabra *et al.*, 1998; Pandey *et al.*, 2007). Numerous pieces of literature claim that the plant contains active ingredients such as costunolide, sitosterol, and cyclocostunolide; guaianolides; cynaropicrin; reynosin; saussurealdehyde; isodehydrocostus-lactone-15-aldehyde; 11,13-epoxy-isoazulananin C; lignin, and glycosides, to name a few.

The word Valerianaceae is derived from “Valere,” a Latin word that means “perfect health.” The Valerianaceae family, which is a source of important phytomedicines like *V. wallichii*, which plays a big

part in Indian medicine (Vaidya, 2002). The most important and well-known active components of this herb include sesquiterpenoids, valepotriates, dihydrovaltrate, isovalerinate, isovaleronic acid, 1-camphene, 1-pinene, 6-methylapigenin, and valepotriates. Hesperidins, isovalerianate, valerianine, and linarin are important bioactive flavonoids that the herb contains, which are responsible for many therapeutic activities of this plant (Hansel *et al.*, 1982; Sah *et al.*, 2010; Katoch *et al.*, 2012; Siddique *et al.*, 2022). Both of these plants are considered safe and relatively non-toxic. Sometimes, any drug may not show toxicity when used individually but can be toxic when used in combination with other drugs. Therefore, the current study is carried out to evaluate the acute oral toxicity of *S. lappa* and *V. wallichii* extracts administered as a single dose of 2000 mg/kg in combination in Wistar rats as per the OECD guideline 423.

### 2. Materials and Methods

#### 2.1 Plant material

The roots of *S. lappa* and *V. wallichii* were purchased from Kisalaya Herbs, Indore, Madhya Pradesh, and authenticated by Dr. K. Madhava Chetty, Associate Professor, Department of Botany, Shri Venkateshwara University, Tirupati (Voucher Numbers: 0761 and 0807, respectively).

The roots were shade-dried and ground into a coarse powder. The extraction process was carried out using a 1:1 mixture of ethanol and water at a temperature not exceeding 80°C in a Soxhlet apparatus. The extracts were stored in an airtight container in a

Corresponding author: Ms. Mrunali S. Potbhare

Datta Meghe College of Pharmacy, Salod (H), Datta Meghe Institute of Higher Education and Research (DU), Sawangi, Wardha-442001, Maharashtra, India

E-mail: [mrunalipotbhare@gmail.com](mailto:mrunalipotbhare@gmail.com)

Tel.: +91-9422442422

Copyright © 2022 Ukaaz Publications. All rights reserved.

Email: [ukaaz@yahoo.com](mailto:ukaaz@yahoo.com); Website: [www.ukaazpublications.com](http://www.ukaazpublications.com)

cool, dry place until further analysis and use. All other chemicals and reagents used in the study were of AR grade.

## 2.2 Acute toxicity assay

### 2.2.1 Test animals

The experiments were carried out in the centralised preclinical facility of DMIHER (Datta Meghe Institute of Higher Education and Research), Sawangi (M), Wardha, Maharashtra. As per the protocol, 6 male wistar rats (3 for the normal control group and 3 for the polyherbal extract group) of body weight between 230 and 290 g were used for the study. The study was approved by IAEC, viz., Ref. No. DMIMS/CPCSEA-IAECPA/20-21/34. The study was conducted as per the guidelines of the CPCSEA. The animals were kept under standard environmental conditions of light (12 h light/dark), temperature ( $25 \pm 5^\circ\text{C}$ ), and humidity throughout the duration of the study. Animals were fed standard pellet diets and water.

### 2.2.2 Acute oral toxicity

As required by standard protocol, all the experimental animals were isolated and kept for acclimatization in standard environmental condition of temperature and light for 3 days prior to actual start of experiments. As per OECD guidelines 423, fixed-dose procedure was followed for carrying out the acute oral toxicity study. The main aim was to study the toxicity of extracts of both the plants when administered together in combination. For this 1:1 mixture of extracts was prepared and used for evaluation acute oral toxicity of both the drugs in combination. Three animals from test groups were administered with 2000 mg/kg of plant extract mixture orally in normal saline solution (NSS) while other three animals in control group received only NSS (Allan *et al.*, 2007; Jothy *et al.*, 2011; Kumar and Lalitha, 2013). The animals were kept under observation for any signs of toxicity for the first 30 min, 4 h and at regular intervals for next 14 days after the administration of combination of extract. Changes in normal behavior and other parameters like body weight, food intake, water intake, temperature, urination, convulsion and tremor were observed as a sign of toxicity (Walum, 1998; Kumar *et al.*, 2014). The animals were sacrificed on 14<sup>th</sup> day using 0.5 ml 50% v/v succinyl choline administered by intra-peritoneal route. Blood sample was collected by cardiac puncture and stored in two different sampling tubes containing EDTA solution. Important visceral organs like brain, heart, liver, kidney and stomach were removed carefully weighed and stored in 40% formalin as fixing solution for further analysis (Jindal *et al.*, 1975; Chanda *et al.*, 2008; Aly *et al.*, 2010).

### 2.2.3 Biochemical analysis

The serum was isolated from a blood sample by centrifugation at about 4000 rpm using a laboratory centrifuge. The biochemical analysis was carried out on the serum to evaluate things like serum creatine, urea, sodium, and potassium levels. Samples were also analysed for cholesterol, H.D.L., V.L.D.L., and cholesterol to H.D.L. ratio, serum globulin, serum albumin, total protein, and the albumin-globulin ratio (Eshome *et al.*, 2008; Mansura, 2011; Patel *et al.*, 2018; Reddy, 2022). The parameters that indicate liver function like SGOT (ALT), SGPT (AST), alkaline phosphate, total bilirubin, direct bilirubin, and indirect bilirubin were estimated to understand the effect of a high dose of extracts on the liver (Adeneye and Olagunga, 2009; Kausar *et al.*, 2010; Garzon *et al.*, 2018).

### 2.2.4 Haematological analysis

The blood samples were also analyzed for complete blood count parameters like hemoglobin (Hb), total RBC, mean corpuscular volume (MCV), mean corpuscular hemoglobin (MCH), total WBC, platelet count, packed cell volume (PVC), and mean corpuscular hemoglobin concentration (MCHC), to observe any abnormal changes which can be indicative of underlying toxic effect (Kunimatsu *et al.*, 2004; Mani *et al.*, 2012; Arsad *et al.*, 2013; Donkor *et al.*, 2014; Wang *et al.*, 2016).

## 3. Results

As per the literature, the tested drug extracts have good therapeutic potential. They are reported for various therapeutic activities individually. In the present study, the acute oral toxicity of *S. lappa* and *V. wallichii* root extracts in combination was evaluated. These drugs can have synergistic activities, including increased toxicity, when used in combination (henceforth addressed as polyherbal extract). The preclinical safety evaluation by single oral dose was carried out according to OECD Guideline 423. The test was performed by administering a dose of 2000 mg/kg of body weight of polyherbal extract with normal saline solution as the vehicle. Test animals were observed with special attention for the first 30 min and then for 4 h and at regular time intervals for a period of 14 days. The animals were observed for any unusual changes in behavior, weight, eating or drinking habits, *etc.* The animals were sacrificed on the 14<sup>th</sup> day, and biochemical and haematological evaluations were performed to understand the signs and symptoms of toxic effects of the administered extract on important parameters. All the results are expressed as the average of all the readings and the standard deviation.

### 3.1 Behavioral pattern

Primary sign of toxicity are changes in normal behavior. The toxic substance effects appearance, salivation, sleep and many such parameters which can be indicative of toxicity. The observations of such parameters which primarily can indicate toxicity are given in Table 1.

**Table 1: Behavioral patterns of experimental animals**

S. No.	Signs/parameters	Observations			
		Normal control (3 Rats)	Rat 1	Rat 2	Rat 3
1.	Fur and skin	N	N	N	N
2.	Respiration	N	N	N	N
3.	Salivation	N	N	N	N
4.	Mucous membrane	NC	NC	NC	NC
5.	Urination (color)	NC	NC	NC	NC
6.	Feces (consistency)	NC	NC	NC	NC
7.	Somatomotor activity and behavior pattern	NC	NC	NC	NC
8.	Sleep	N	N	N	N
9.	Convulsions and tremors	Nil	Nil	Nil	Nil
10.	Itching	Nil	Nil	Nil	Nil
11.	Mortality	Nil	Nil	Nil	Nil
12.	Any other symptoms	NF	NF	NF	NF

N= Normal; NC=No change; NF=Not found.

The results show that from 0 days to 14<sup>th</sup> day of study for acute oral toxicity, no changes in behavior were observed.

### 3.2 Bodyweight and organ weight

Toxic substance or adverse reaction can cause alteration in body weight. The weight of rats was noted after administration of drug at single dose on 1<sup>st</sup>, 7<sup>th</sup> and 14<sup>th</sup> day of the experiment. All the animals were having normal body weights and no significant changes were observed in animal weights during study period. The body weights of normal group as well as study group were within normal range and no drastic changes were noted. The results are depicted in Figure 1.

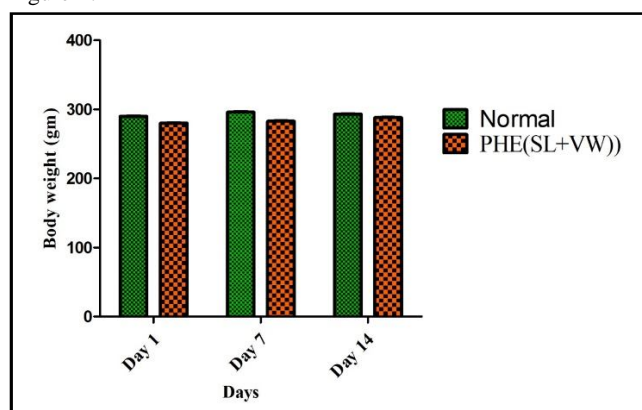


Figure 1: Effect of the extracts on body weight.

Weight of vital organs was recorded after sacrificing animals after completion of study, *i.e.*, 14 days. No gross changes were observed in weight of the vital organs like brain, heart, liver, kidney and stomach. The toxicity of administered drug can result in changes in functioning of vital organs resulting in their weight change. No significant changes were observed in experimental animals indicating no toxicity. The results of estimation of organ weight are presented in Figure 2.

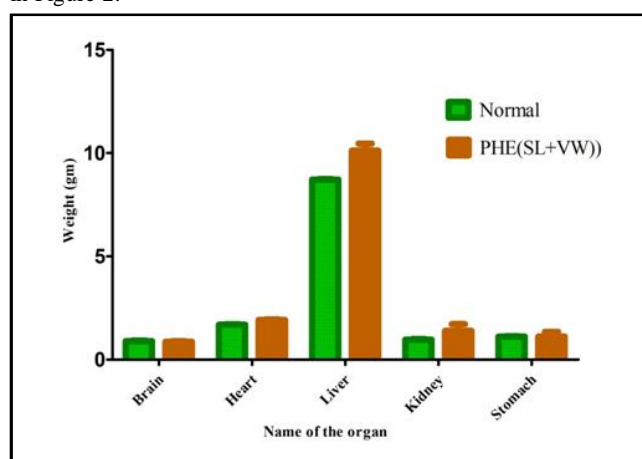


Figure 2: Organ weight in grams.

### 3.3 Biochemical parameters

Serum samples of experimental animals groups were evaluated for various parameters like serum creatine, serum urea, serum sodium and serum potassium. These parameters have a stable and fix range

in healthy individuals. Any significant change in their level can be an indication of underlying toxicity. The results indicate that there are no significant changes in all the analyzed biochemical parameters of the experimental group who were administered 2000 mg/kg of herbal extract like that of the control group indicating no signs of oral acute toxicity. The results of biochemical evaluation are represented in Figure 3.

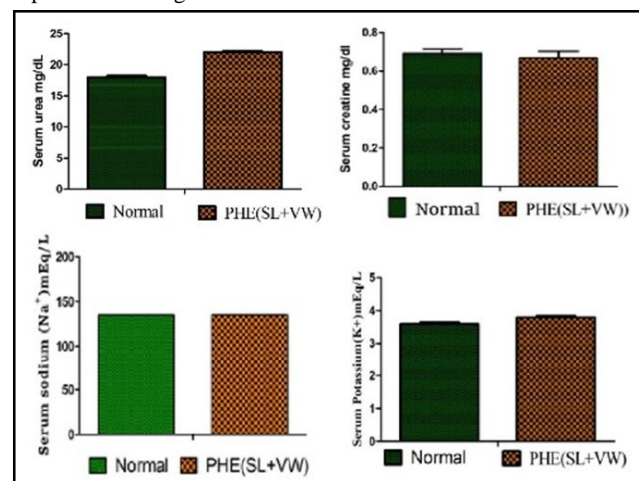


Figure 3: Biochemical parameters of experimental rats.

### 3.4 Lipid profiling

Lipid profiling is carried out to know the serum levels of lipids both useful and harmful. High serum lipid levels are dangerous for cardiovascular system and may lead to many complications like heart failure, *etc.* It also indicates the functioning of liver. It was observed from the results that all the parameters like; VLDL, Cholesterol, HDL and cholesterol: HDL ratio evaluated as a part of lipid profiling, were having normal values in both experimental and normal group. Thus, indicating no oral toxicity at the dose of 2000 mg/kg. Figure 4 shows the results of lipid profiling test for both the experimental groups.

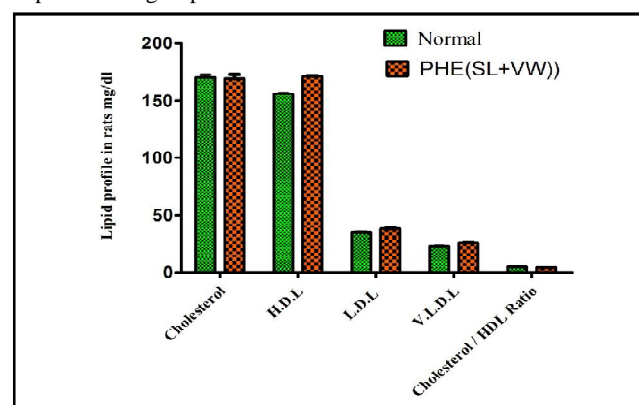


Figure 4: Lipid profile of experimental rats.

### 3.5 Hematological analysis

Blood samples of all the animals were evaluated for the important hematological parameters. Hemoglobin level, total RBC and WBC counts, % hematocrit, mean cell volume (MCV) and mean cell hemoglobin concentration (MCHC) were studied. Toxic effects or

adverse reactions may change the hematological parameters from normal value as an indication of toxicity. The results which are depicted in Figure 5 shows no significant changes in animals

administered combination of extracts when compared to control group animals indicating no acute oral toxicity.

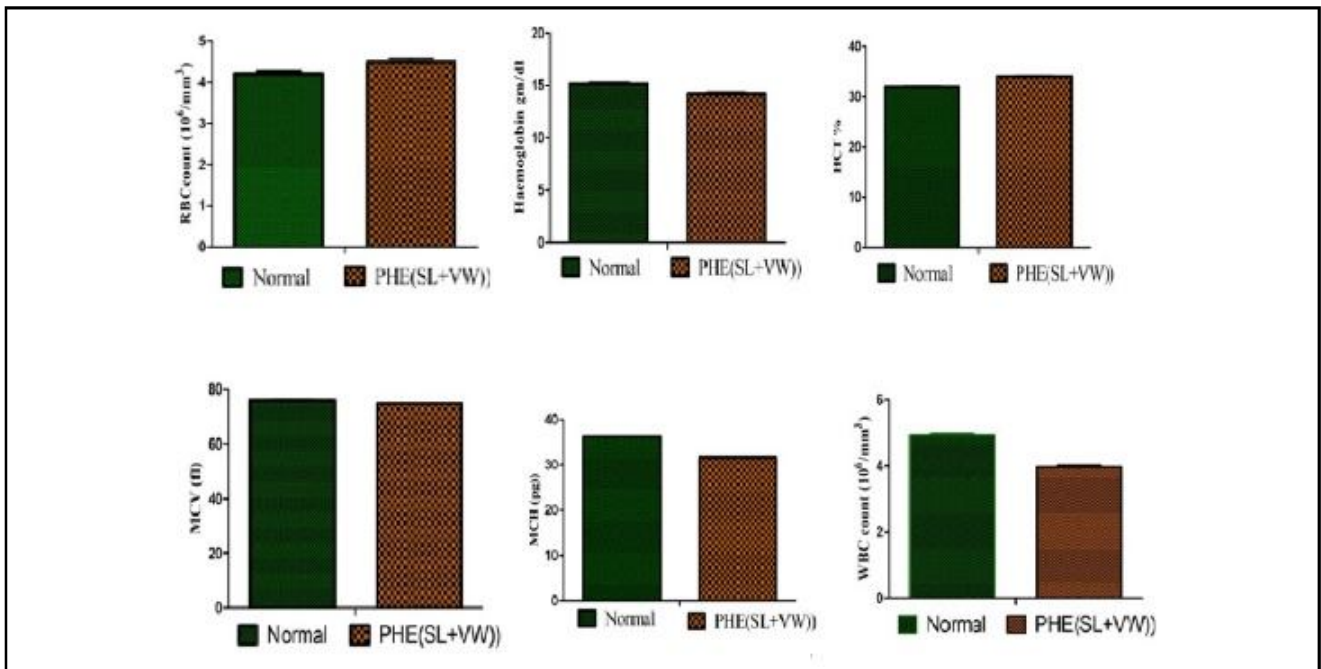


Figure 5: Hematological evaluation of the extracts.

3.6 Liver function test

Blood samples of all the experimental animals were studied for SGPT, SGOT, serum albumin, serum globulin, alanine phosphate, total bilirubin, albuminglobulin ratio, indirect bilirubin and direct bilirubin. These parameters indicate the health of liver. Healthy

liver shows normal values for all these parameters. The results show no significant changes in evaluated Liver function tests. Both the experimental group (2000 mg/kg poly-herbal root extract) and normal treated groups show values within limit. These parameters were represented in Figure 6.

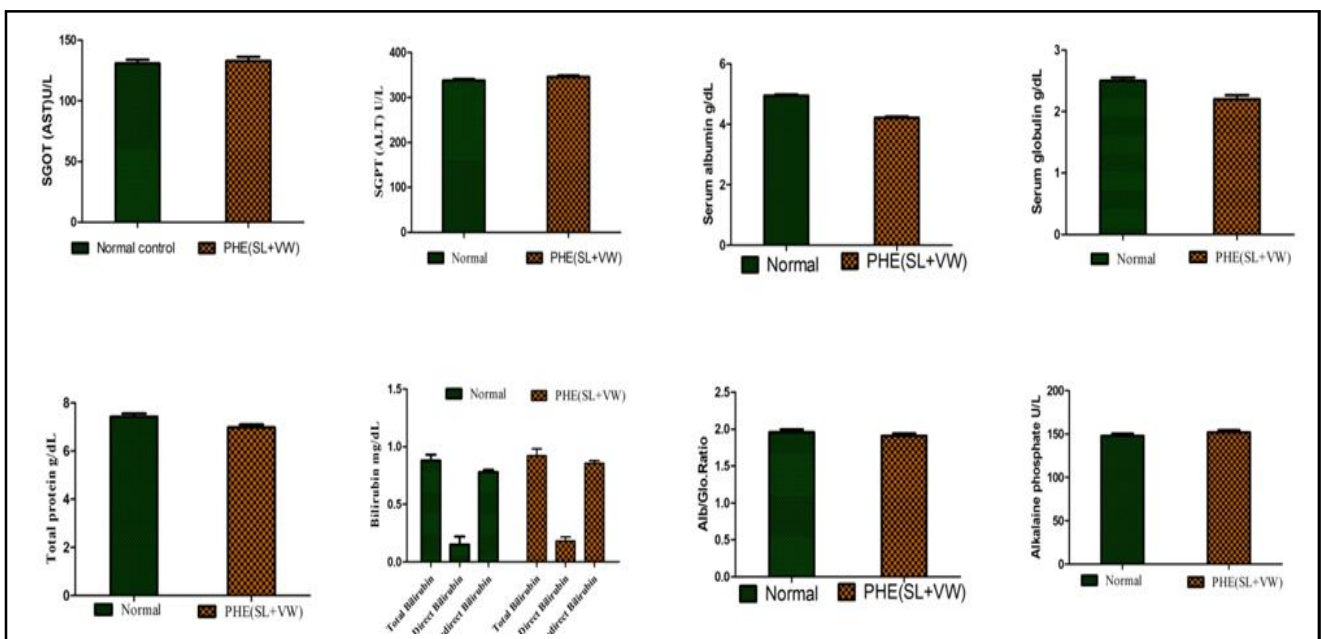


Figure 6: Liver function tests in experimental rats.



#### 4. Discussion

The oral acute toxicity was used in the current investigation to gather information on the toxicity of the polyherbal extract consisting of a 1:1 ratio of hydroalcoholic extracts of *S. lappa* and *V. wallichii*. The primary goal of the acute toxicity study was to determine the level of negative effects that the polyherbal extract had on the experimental animal's specific organs at an oral dose of 2000 mg/kg. The results revealed that polyherbal extract at an administered level of 2000 mg/kg did not cause any animal mortality or behavioural abnormalities. The polyherbal extract can therefore be allocated to the lowest toxicity class 5 ( $LD_{50} > 2000$  mg/kg) in accordance with OECD guidance (OECD, 2001). Additionally, a negligible variation in the weight of the vital organs of animals from the normal control group and polyherbal extract-treated groups shows that polyherbal extract did not produce any sensitivity, change, or acute organ damage.

According to Adeneye *et al.* (2006), hemological measures are extremely critical indicators of drug-induced toxicity. The findings of the haematological study did not reveal any notable changes in the experimental animal group when compared to the normal control group. There were no noticeable differences between the biochemical parameters of the normal control group and the polyherbal extract group, and all tested parameters were within the normal range.

The earliest and most important markers for evaluating liver damage are plasma levels of AST and ALT (Hassanpour *et al.*, 2015). When the plasma membrane of the hepatocyte is disrupted, the enzymes that are normally found in the cytosol of liver cells leak out into the bloodstream, indicating abnormalities with liver structure and function. Total blood cholesterol has a direct correlation with many life-threatening conditions like diabetes, hypertension, and cardiovascular disorders; monitoring plasma levels of this substance is crucial in toxicological investigations (Lima *et al.*, 2017). Polyherbal extract did not significantly alter the blood cholesterol, bilirubin, or other indicators of LFT in experimental animals when compared with the normal control group. The plasma levels of total protein increased significantly after receiving the polyherbal extract dose (2000 mg/kg). This outcome is cognizant of that reported by Musa *et al.* (2017), who noted a substantial rise in total protein in experimental female rats. This outcome suggests that the organs were not harmed, but overall protein synthesis may have increased. The kidneys are extremely vulnerable to injury by medications or herbs because they play a crucial role in the excretion of metabolites and drugs, in controlling blood flow, and in numerous metabolic processes (Taheri *et al.*, 2016; Baudoux and Nortier, 2017). There was no discernible difference in blood creatine, serum urea, serum sodium, or serum potassium between the treatment group and normal control group rats, suggesting that polyherbal extract may be safe and nontoxic to the kidney. From the overall results of the oral acute toxicity study, the polyherbal extract can be considered safe and devoid of any acute toxicity.

#### 5. Conclusion

The herbal drug alternative is considered very safe as compared to synthetic drugs. But, it is not the case, as many herbal drugs are very poisonous. Therefore, herbal drugs must also be evaluated for toxic effects to prove their safety. The study was aimed at evaluating the oral acute toxicity of a polyherbal extract of *S. lappa* and *V.*

*wallichii*. The combination of extracts in a 1:1 ratio was administered in a single dose of 2000 mg/kg of body weight. The results indicate that there are no major changes in body or organ weight, with the behaviour primarily indicating no oral toxicity at the administered dose. The analysed biochemical and haematological parameters also show no significant changes, indicating no oral toxicity. The results indicate that the analysed plants of *S. lappa* and *V. wallichii* are non-toxic even in combination and can be used for various clinical indications in combination.

#### Conflict of interest

The authors declare no conflicts of interest relevant to this article.

#### References

- Adeneye, A. and Olagunju, J.A. (2009). Preliminary hypoglycemic and hypolipidemic activities of the aqueous seed extract of *Carica papaya* Linn in Wistar rats. *Biology and Medicine*, 1(1):1-10.
- Adeneye, A.; Ajagbonna, O.; Adeleke, T.I. and Bello, S.O. (2006). Preliminary toxicity and phytochemical studies of the stem bark aqueous extract of *Musangacecropioides* in rats. *Journal of Ethnopharmacology*, 105(3):374-9.
- Allan, J.J.; Damodaran, A.; Deshmukh, N.S. and Goudar, K.S. (2007). Safety evaluation of a standardized phytochemical composition extracted from *Bacopa monnieri* in Sprague-Dawley rats. *Food and Chemical Toxicology*, 45(10):1928-37.
- Aly, A.H.; Debbab, A.; Kjer, J. and Proksch, P. (2010). Fungal endophytes from higher plants a prolific source of phytochemicals and other bioactive natural products. *Fungal Diversity*, 41(1):1-16.
- Arsad, S.S.; MohdEsa, N.; Hamzah, H. and Othman F. (2013). Evaluation of acute, subacute and subchronic oral toxicity of *R. decursiva* (Roxb.) Schott extract in male Sprague-Dawley rats. *Journal of Medicinal Plant Research*, 7(41):3030-40.
- Baudoux, T. and Nortier, J.L. (2017). Nephrotoxicity of herbal products. *Toxicology of Herbal Products*. New York: Springer International Publishing, 307-344.
- Biradar, D.P. (2015). Medicinal plants and phytomedicines. *Ann. Phytomed.*, 4(1):1-5.
- Chanda, D.; Shanker, K.; Pal, A.; Luqman, S.; Bawankule, D.U.; Mani, D.N. and Darokar, M.P. (2008). Safety evaluation of Trikatu, a generic Ayurvedic medicine in Charles Foster rat. *Journal of Toxicological Science*, 34(1):99-108.
- Chen, H.C.; Chou, C.K.; Lee, S.D.; Wang, J.C.; Yeh, S.F. (1995). Active compounds from *Saussurea lappa* Clarke that suppress hepatitis B virus surface antigen gene expression in human hepatoma cells. *Antiviral Research*, 27:99-109.
- Chhabra, B.R.; Gupta, S.; Jain, M. and Kalsi, P.S. (1998). Sesquiterpene lactones from *Saussurea lappa*. *Phytochemistry*, (49):3801-3804.
- Donkor, K.; Okine, L.N.K.; Abotsi, W.K.M. and Woode, E. (2014). Acute and sub-chronic toxicity studies of aqueous extract of root bark of *Cassia sieberiana* DC in rodents. *Journal of Applied Pharmaceutical Science*, 4(04):084-089.
- Eshome, K.; Gebre-Mariam, T.; Asres, K.; Perry, F. and Engidawork, E. (2008). Toxicity studies on dermal application of plant extract of *P. zeylanica* used in Ethiopian traditional medicine. *Journal of Ethnopharmacology*, 117(2):236-48.
- Garzon, F.; Coimbra, D.; Parcerisas, A. and Rama, R. (2018). Neuro EPO preserves neurons from glutamate-induced excitotoxicity. *Journal of Alzheimer's Disease*, 65(4):1469-1483.

- Hansel, R.; Schultz, J.; Valerensäuren, Und.; Valerenals Leitstoffe, des. and Offizinellen, Baldrians. (1982). Bestimmungsmittels HPLC-Technik. Deutsche Apotheker Zeitung, 122:333-340.
- Hassanpour, F. M.; Naseh, G.; Lotfi, N.; Hosseini, S.M. and Hosseini, M. (2015). Effects of aqueous extract of turnip leaf (*brassica rapa*) in alloxan-induced diabetic rats. Avicenna Journal of Phytomedicine, 5(2):148-56.
- Jindal, M.N.; Patel, V.K. and Patel, N.B. (1975). Pharmacological actions of aqueous and alcoholic extracts of roots of *Cichorium intybus* Linn. Indian Journal of Pharmacology, 7(3):24-33.
- Jothy, S.L.; Zakaria, Z.; Chen, Y.; Lau, Y.L.; Latha, L.Y. and Sasidharan, S. (2011). Acute oral toxicity of methanolic seed extract of *Cassia fistula* in Mice. Molecules, 16:5268-5282.
- Katoch, O.; Kaushik, S.; Sadashiv, M.; Kumar, Y.; Paban, K. and Agrawala, M. K. (2012). Radioprotective property of an aqueous extract from *Valerian wallichii*. Journal of Pharmacy and Bioallied Sciences, 4:4.
- Kausar, M.W.; Moed, K.; Asif, N.; Rizwi, F. and Raza, S. (2010). Correlation of bilirubin with liver enzymes in patients of falciparum malaria. International Journal of Pathology, 8(2):63-67.
- Kumar, P.; Suba, M.; Ramireddy, B and Srinivas, P. (2014). Acute and Sub-Acute 28-Day Oral Toxicity studies of ethanolic extract of *Celtis timorensis* leaves in rodents. Global Journal of Medical Research, 14(3):1-9.
- Kumar, V.K. and Lalitha, K.G. (2013). Acute oral toxicity studies of *Anacyclus pyrethrum* DC. root in albino rats. International Journal of Pharmacy and Pharmaceutical Sciences, 5(4):675-678.
- Kunimatsu, T.; Yamada, T.; Miyata, K.; Yabushita, S.; Seki, T. and Okuno Y. (2004). Evaluation for reliability and feasibility of the draft protocol for the enhanced rat 28-day subacute study (OECD Guideline 407) using androgen antagonist flutamide. Toxicology, 200(1):77-89.
- Lima, D. F.; Traesel, G.K.; Menegati, S.E.; Santos, A.C.; Souza, R.I.; and Oliveira, V.S. (2017). Acute and subacute oral toxicity assessment of the oil extracted from *attalea phalerata martin spring* fruit Pulp fruit in rats. Food Research International, 91:11-17.
- Mansura, A. (2011). Effect of *peristrophe bicalyculata* on lipid profile of P-407 induced hyperlipidemic Wistar rats. Journal of Medicinal Plants Research, 5(4): 490- 494.
- Mani, V.; Ramasamy, K.; Ahmad, A.; Parle, M.; Shah, S.A. A.; and Majeed, A. B. A. (2012). Protective effects of total alkaloidal extract from *Murraya koenigii* leaves on experimentally induced dementia. Food and Chemical Toxicology, 50(3-4):1036-1044.
- Musa, C.; Furaha, N. and Edna, M. (2017). Acute and subacute oral toxicity evaluation of *Commiphora campestris* methanolic stem bark extract (CASBMCE) In Mice and Rats. Journal of Complementary Medicine and Alternative Healthcare, 4(1):1-11.
- OCDE (2001). OECD Guidelines for the Testing of Chemicals, Number 423 Acute Oral Toxicity-Acute Toxic Class Method, adopted 17<sup>th</sup> December 2001.
- Pandey, M.M.; Rastogi, S. and Rawat, A.K.M. (2007). *Saussurea costus*: Botanical, chemical and pharmacological review of Ayurvedic medicinal plant. Journal of Ethnopharmacology, 110:379-390.
- Patel, A.G.; Mukeshkumar, B. and Nariya, S.D. (2018). Acute toxicity and repeated dose 28-day oral toxicity study of metriviv syrup in female rats. An International Quarterly Journal of Research in Ayurveda, 39(2):107-12.
- Reddy, M.V.B. (2022). Isolation, characterization and structure elucidation of flavonoids from the root bark of *Bauhinia variegata* L. Ann. Phytomed., 11(1):673-679.
- Sah, S. P.; Mathela, C. M. and Chopra, K. (2010). Elucidation of possible mechanism of analgesic action of *Valeriana wallichii* DC. (Patchouli alcohol) in experimental animal models. Indian Journal of Experimental Biology, 48:289-293.
- Siddique, M.; Khan, H. M.; Kanwal, A.; Syed, F.; Riaz, H.; Muhammad, S.; Malik, R.A.; Asim, F.; Raza, M. and Umair, S. (2022). Nootropic evaluation of methanolic bark extract of *Murraya koenigii* (L.) against scopolamine and diazepam induced memory dysfunction in mice. Ann. Phytomed., 11(1):333-337
- Taheri, H.; Hosseini, M.; Hassanpour, M.; Fard, M.; Ghiravani, Z.; Darmiyan, V. K. and Yousefi, S. (2016). Effect of turnip leaf and root extracts on renal function in diabetic rats. Oriental Pharmacy and Experimental Medicine, 16(4):279-86.
- Vaidya, B. (2002). Nighantu, Adarsa. 3<sup>rd</sup> ed. Varanasi: Chaunkhamba Bharati Academy; pp:734.
- Walum, E. (1998). Acute oral toxicity. Environmental Health Perspectives, 106(S2):497-503.
- Wang, Z.; Jiajia, W.; Xuelian, Y.; Pei, C. ; Qiaohong, L.; Wang, K.D.G.; Kong, L. and Wang, X. (2016). Neuroprotective effects of benzyloxy substituted small molecule monoamine oxidase B inhibitors in Parkinson. Bioorganic and Medicinal Chemistry, 24(22):5029-40.

## Citation

Mrunali S. Potbhare, Rakesh Barik and Deepak S. Khobragade (2022). Preclinical appraisal of acute oral toxicity of combination of root extracts of *Saussurea lappa* (Decne.) Sch.Bip. and *Valeriana wallichii* (DC.). Ann. Phytomed., 11(2):405-410. <http://dx.doi.org/10.54085/ap.2022.11.2.49>.